




Glässer's disease in swine from Northeastern Brazil¹

Hisadora A.S.C. Bom², Givaldo B. Silva Filho², Elayne G. Silva², Mylena R. Pereira²,
Silvio M.C. Fonseca², Rikki Boswell³, Valdir M. Almeida⁴, Francisco A.L. Souza⁵ 
and Fábio S. Mendonça^{5*} 

ABSTRACT.- Bom H.A.S.C., Silva Filho G.B., Silva E.G., Pereira M.R., Fonseca S.M.C., Boswell R., Almeida V.M., Souza F.A.L. & Mendonça F.S. 2020. **Glässer's diseases in swine from Northeastern Brazil.** *Pesquisa Veterinária Brasileira* 40(9):662-668. Laboratório de Diagnóstico Animal, Universidade Federal Rural de Pernambuco, Rua Dom Manoel de Medeiros s/n, Dois Irmãos, Recife, PE 52171-900, Brazil. E-mail: fabio.mendonca@ufrpe.br

Glässer's disease is an important infectious disorder of swine caused by *Haemophilus parasuis*. Although well recognized in most regions of Brazil, outbreaks of Glässer's disease have not been described in Northeastern region. For this reason, three municipalities of the Pernambuco State were visited in order to identify histories of high mortality in growing and finishing pigs. The main clinical signs consisted of dry cough, apathy, fever, anorexia, paresis, muscle tremors, motor incoordination, seizures leading to high mortality rates. Nine pigs were necropsied, and fragments of the nervous system, organs of the abdominal and thoracic cavities were collected for histological analysis. In addition, lung and brain fragments were used for DNA extraction and molecular testing by real-time Polymerase Chain Reaction (PCR). Grossly, the main lesions consisted of petechial hemorrhages or ecchymosis on the skin of the face, abdomen, forelimbs, and hind limbs. The main severe lesions consisted of hydropericardium, hemopericardium, fibrinous pericarditis and pleuropneumonia. Microscopically, pericarditis, epicarditis and subepicardial myocarditis, followed by a moderate to severe multifocal pleuropneumonia, fibrinosuppurative and necrotizing were the most frequent lesions observed. Real-time PCR amplified *H. parasuis infB* gene in all samples analyzed, confirming the presence of this etiologic agent.

INDEX TERMS: Glässer's diseases, swine, Brazil, pneumonia, polyserositis, meningitis, *Haemophilus parasuis*.

RESUMO.- [Doença de Glässer em suínos no Nordeste do Brasil.] A doença de Glässer é uma importante enfermidade infecciosa de suínos causada pela bactéria *Haemophilus parasuis*. Embora bem reconhecida na maioria das regiões do Brasil, surtos de doença de Glässer não têm sido descritos na região Nordeste. Por este motivo, três regiões do Estado de

Pernambuco foram visitadas com o objetivo de se identificar históricos de alta mortalidade em leitões e suínos em fase de terminação. Nove suínos foram necropsiados e fragmentos do sistema nervoso, órgãos das cavidades abdominal e torácica foram coletados para análise histopatológica. Além disso, fragmentos de pulmão e cérebro foram utilizados para extração de DNA e realização de teste molecular por meio da Reação em Cadeia da Polimerase (PCR) em tempo real. Os principais sinais clínicos consistiram em tosse seca, apatia, febre, anorexia, paresia, tremores musculares, incoordenação motora e convulsões levando a altas taxas de mortalidade. As lesões macroscópicas mais severas consistiam em petéquias e equimoses na pele da face, abdome, membros anteriores e posteriores, além de hidropericárdio, hemopericárdio, pericardite fibrinosa e pleuropneumonia. Microscopicamente, pericardite, epicardite e miocardite subepicárdica, seguidas de pleuropneumonia multifocal moderada a grave, fibrinosuppurativa e necrosante foram as lesões mais frequentes observadas. A PCR em tempo real amplificou o gene *infB* de

¹Received on July 8, 2020.

Accepted for publication on July 23, 2020.

²Postgraduate Program in Veterinary Medicine, Universidade Federal Rural de Pernambuco (UFRPE), Rua Dom Manuel Medeiros s/n, Dois Irmãos, Recife, PE 52171-900, Brazil.

³College of Veterinary Medicine, Western University of Health Sciences, 309 E. Second, St. Pomona, CA 91766-1854, United States.

⁴Veterinary Hospital, Universidade Federal de Campina Grande (UFCG), Patos, PB 58700-000, Brazil.

⁵Laboratório de Diagnóstico Animal (LDA), Universidade Federal Rural de Pernambuco (UFRPE), Rua Dom Manuel Medeiros s/n, Dois Irmãos, Recife, PE 52171-900, Brazil. *Corresponding author: fabio.mendonca@ufrpe.br

H. parasuis em todas as amostras analisadas, confirmando a presença deste agente etiológico.

TERMOS DE INDEXAÇÃO: Doença de Glässer, suínos, Brasil, pneumonia, poliserosite, meningite, *Haemophilus parasuis*.

INTRODUCTION

Glässer's disease (GD) is an infectious disorder caused by the pleomorphic, Gram-negative bacterium of the Pasteurellaceae family, *Haemophilus (Glaesserella) parasuis* (Biberstein & White 1969, Dickerman et al. 2020), which infects members of the Suidae family, such as domestic swine and wild boars (Møller & Kilian 1990, Vengust et al. 2006, Gerveno et al. 2013). *H. parasuis* is a common inhabitant of the upper respiratory tract of conventionally raised pigs. The infection usually remains subclinical (Oliveira & Pijoan 2004) and emerge mainly in herds of piglets and juveniles pigs during stress-associated events including coinfections, moving and especially when piglets from different sources are mixed (Rafiee & Blackall 2000, Cai et al. 2005, Brockmeier et al. 2014).

GD occurs in swine populations worldwide irrespective of health status and outbreaks are economically significant because certain *H. parasuis* serovars cause high mortality rates, resulting in substantial production losses and increased costs, mainly due to the use of antibiotics (Møller et al. 1993, Nedbalcova et al. 2006). In the United States, GD is considered one of the main infectious problems in the nursery, also affecting growing pigs and sows (Holtkamp et al. 2007) and in Brazil, *H. parasuis* has been commonly isolated in swine farms at Central-Western, Southeastern and South regions of the country (Espíndola et al. 2019) being frequent, in the large, better and herds with good health status (Zanella et al. 2016).

H. parasuis strains are heterogeneous in phenotypic and genotypic traits. Fifteen variants are described and are classified according to the degree of virulence as high, moderate and non-virulent serotypes (Kielstein & Rapp-Gabrielson 1992). Most isolates of *H. parasuis* in Brazil are the virulent serotypes SV1, SV4 and SV5. But a large number of serovars consists of non-typed isolates (Espíndola et al. 2019). For this reason, the clinical picture could be variable, depending on the infecting strain. More than one serotype could be implicated in outbreaks of GD, and generally, the clinical picture is correlated with pneumonia, fibrinous polyserositis, polyarthritis and meningitis (Little 1970, Amano et al. 1994).

Clinical signs are mainly observed in 4 to 8-week-old pigs. Infected ones show high fever (41.5°C), dry cough, abdominal breathing, arthritis and nervous signs such as tremors, pedaling movements and lateral recumbency. Sporadically, GD is also observed in adult pigs. Initial diagnosis should be made by clinical and histopathological findings, however, ancillary tests are required for diagnostic confirmation and maybe performed as definitive by bacterial isolation, antibody detection, immunohistochemistry or through molecular tests such as PCR and serotyping (Nedbalcova et al. 2006, Olvera et al. 2012).

GD is still present in pig farms, and the importance of an accurate diagnosis becomes currently more importance to aiming to reduce the use of antibiotics (Aragon et al. 2019). Considering the information provided here, and the few information about the occurrence of GD in pigs at Northeastern

Brazil, we aim to report the epidemiological, clinical and pathological aspects of three outbreaks of Glässer's disease in the State of Pernambuco.

MATERIALS AND METHODS

Three outbreaks of GD were accompanied from 2016 to 2018, in the state of Pernambuco, northeastern Brazil. Epidemiological, clinical and pathological data were obtained from interviews with the owners and from technical visits to those properties. Two piglets in the first outbreak, five in the second and eight in the third were separated from the herd and clinically evaluated for general condition, behavior, respiratory and cardiac rates, coordination, head posture, movement, rectal temperature and appearance of feces, urine and skin.

One swine from the first outbreak, four from the second and five from the third were necropsied and fragments of tissues from the CNS (brain, cerebellum, brainstem and medulla), thoracic cavity (lung and heart) and abdominal cavity (liver, kidney, spleen, pancreas and intestines), as well as the lymphatic system (tonsils, retropharyngeal and mesenteric lymph nodes) were collected. These fragments were fixed in 10% formalin solution were routinely processed for inclusion in paraffin blocks, cutted at 4µm and stained with hematoxylin-eosin (HE) for microscopy analysis.

Samples of lung and brain were used for DNA extraction and molecular analysis using real-time Polymerase Chain Reaction for *Haemophilus parasuis* identification. For this, approximately 1cm³ of tissue (corresponding to 180-280mg) was diluted in sterile saline phosphate buffer (PBS, pH 7.4) and then homogenized. 200µL of DNA from the homogenized tissues were extracted using a commercial kit according to the manufacturer's protocol. A protocol of real-time Polymerase Chain Reaction previously established by Turni et al. (2009) was used. Additionally, the samples were also tested for *Mycoplasma hyopneumoniae* using the protocol previously described by Dubosson et al. (2004) and circovirus type 2 (Oh et al. 2006).

RESULTS

Three outbreaks were accompanied during two years in different regions of Pernambuco, Northeastern Brazil. The first one occurred in the municipality of Cabo de Santo Agostinho (8°17'02" S, 35°3'54" W), in the Coastal Region, the second one in the municipality of Paudalho (7°92'84" S, 35°15'82" W), at the Forest Zone and the third in the municipality of Exu (7°49'80" S, 39°71'67" W), at the Semi-arid Region (Fig.1). All those properties were small commercial farms or raised backyard pigs (where families kept pigs at home, mostly for personal consumption and extra income). The pigs were

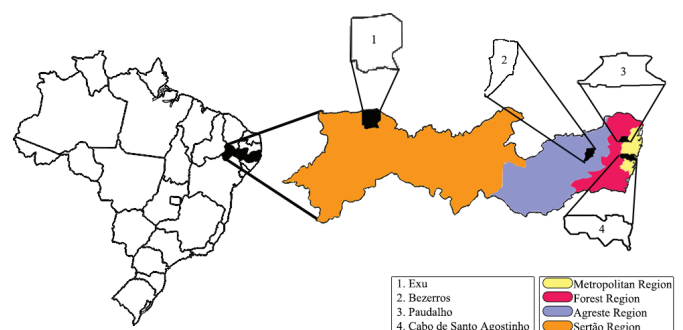


Fig.1. At the left is the map of Brazil. The state of Pernambuco and the municipalities where the outbreaks occurred are magnified.

kept in pens in groups separated by age (adults, juveniles or piglets) and category (boars, gilts, or sows), and no one of the properties had significant sanitary controls, vaccination program, or veterinary monitoring. The alimentary management were composed mainly by leftover food, and pigs also received crushed corn and commercial food intermittently.

The main history complaint obtained from the owners were similar; all of them reported tremors followed by high mortality rates, mainly in piglets aging of 2 months old on average. In the first property at municipality of Cabo de Santo Agostinho, 80 crossbred pigs were raised (2 boars, 27 sows and 51 piglets) and of these, one sow and 46 piglets died after presenting seizures, fever, and petechial hemorrhages, mainly on the skin of the ears, face, and legs.

In Paudalho, 50 crossbred Pietrain pigs were raised (3 boars, 20 sows, and 27 pigs in the growing and finishing phase). GD started after the introduction of 25 piglets from the municipality of Bezerros (8°25'72" S, 35°74'73" W), at the Agreste region, bought from an online classifieds' platform and without veterinary assistance. Despite noting that some of the piglets were apathetic, and coughing, no quarantine period was provided, and the owner integrated the new pigs with the present stock upon receiving them. Five days after the

introduction of the new pigs, clinical signs were observed in the piglets. During the technical visit, it was observed dry cough, apathy, and fever ranging from 41°C to 42°C, muscle tremors, motor incoordination, permanent lateral recumbency, seizures and death. The piglets also remained huddled together and presented petechiae and ecchymosis on their skin. One boar presented respiratory distress and a "dog-sitting" position (Fig.2A). All those piglets (69%, 52/75), the boar and a sow died showing one or more of these clinical signs less than 12 days after the first clinical signs were observed.

In the third outbreak occurred in the municipality of Exu, 123 crossbred pigs (Landrace x Pietrain) were raised (3 boars, 20 sows, and 100 young pigs in the growing and finishing phase). From 100 young pigs, 18 (18%) presented clinical signs similar to those previously reported, and all of them died between one to seven days after the observation of the first clinical signs. Seven days later, more 20 health piglets were bought and introduced into the herd. Those pigs presented the same clinical picture and died in less than 10 days after arriving. The survivor's piglets become undeveloped, were underweight, apathetic and also presented locomotor difficulty (Fig.2B) and rough hair. The owner then decided to cull the pigs which were necropsied.

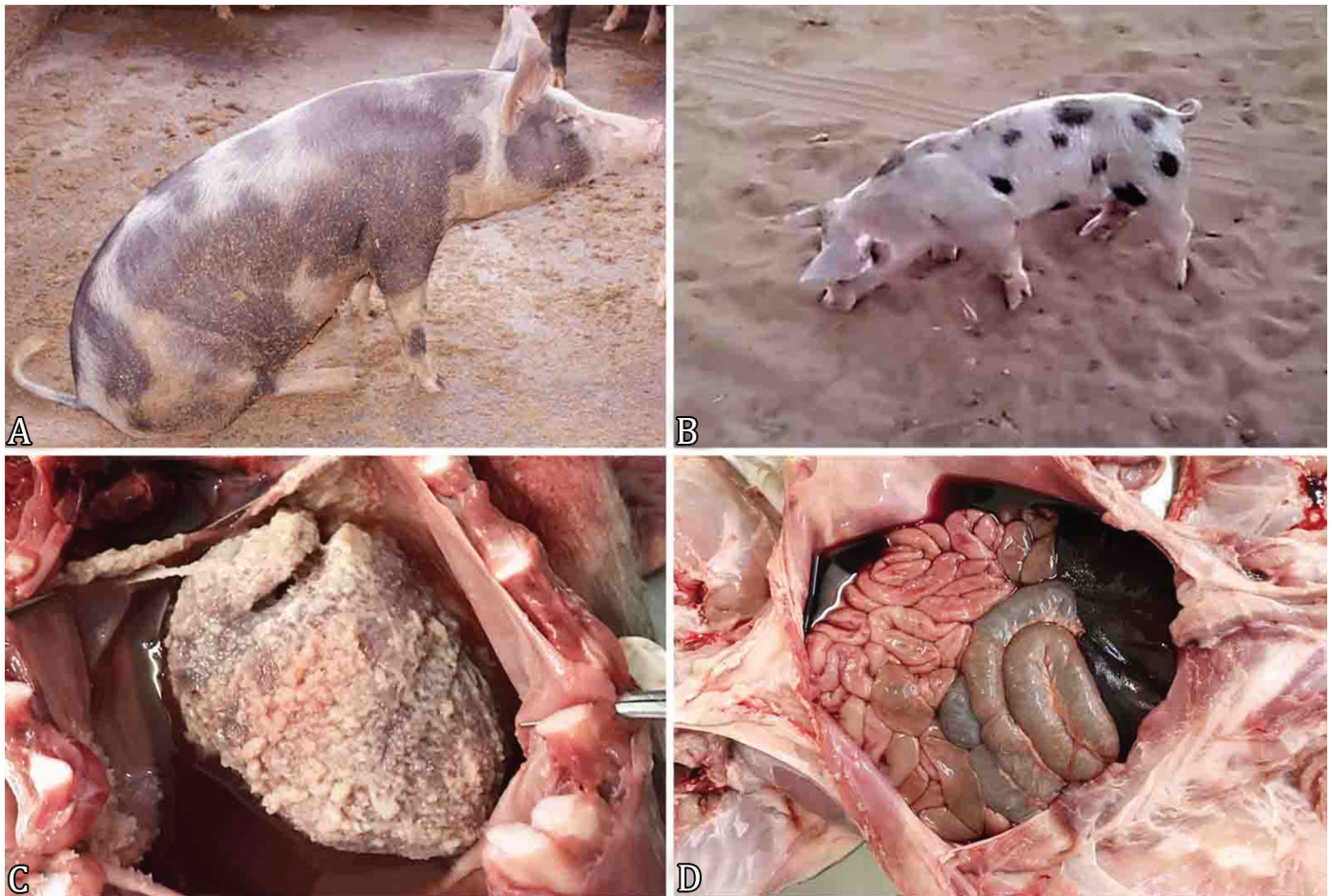

Fig.2. Clinical signs and necropsy findings of Glässer's disease. (A) Boar at rest in unusual "dog-sitting" position due to respiratory distress. (B) Swine with locomotor difficulty and dragging the clamp on the ground. (C) Abundant amount of fibrin covering the visceral and parietal layers of the pericardium (fibrinous pericarditis) and moderate amount of serous fluid filling the thorax cavity (hydrothorax). (D) Moderate amount of blood content in the abdomen and severe liver congestion.

Gross findings were similar, being variable according to the severity, and consisted of hemorrhages ranging from petechiae to ecchymosis on the skin of the face, abdomen, forelimbs and hind limbs. Five out of ten piglets (50%) had lesions associated with the heart which consisted of hydropericardium, hemopericardium and/or fibrinous pericarditis (Fig.2C). In these cases, there were also fibrinous pleuritis with adherence of the pleura and pericardial sac to the chest wall. Petechial hemorrhages in the lungs with multifocal areas of hepatization and pneumonia, mostly bilateral and accumulation of citrine fluid content, but also containing blood in the abdominal cavity were common findings (Fig.2D). The presence of other lesions was variable, but also included polyserositis characterized by fibrinopurulent exudate on serosal membranes from the abdominal cavity, mesenteric hyperemia, edema of the mesenteric lymph nodes and congestion of the liver, spleen, and kidney. In the central nervous system, mild meningeal

thickening and leptomenigeal vessel congestion were noted in two necropsied piglets.

Microscopically, a moderate to severe pleuropneumonia, fibrinosuppurative and necrotizing, acute to subacute, multifocal with moderate numbers of degenerate neutrophils, fewer lymphocytes, plasma cells and macrophages were the main morphological diagnosis performed. Sometimes, hyperplasia of type II pneumocytes were also noted. Additionally, in most cases, the pleura was diffusely and moderately expanded by a mixed aggregate of inflammatory cells and fibrin (Fig.3A). Usually, the alveolar and bronchiolar lumina contained inflammatory exudate, admixed with fibrin and necrotic debris. The bronchiolar epithelial cells were multifocally necrotic, and generally, there was BALB's hyperplasia (Fig.3B). In the heart, common lesions consisted of epicarditis and subepicardial myocarditis, mainly fibrinosuppurative and necrotizing, with infiltration of degenerated neutrophils, histiocytes and

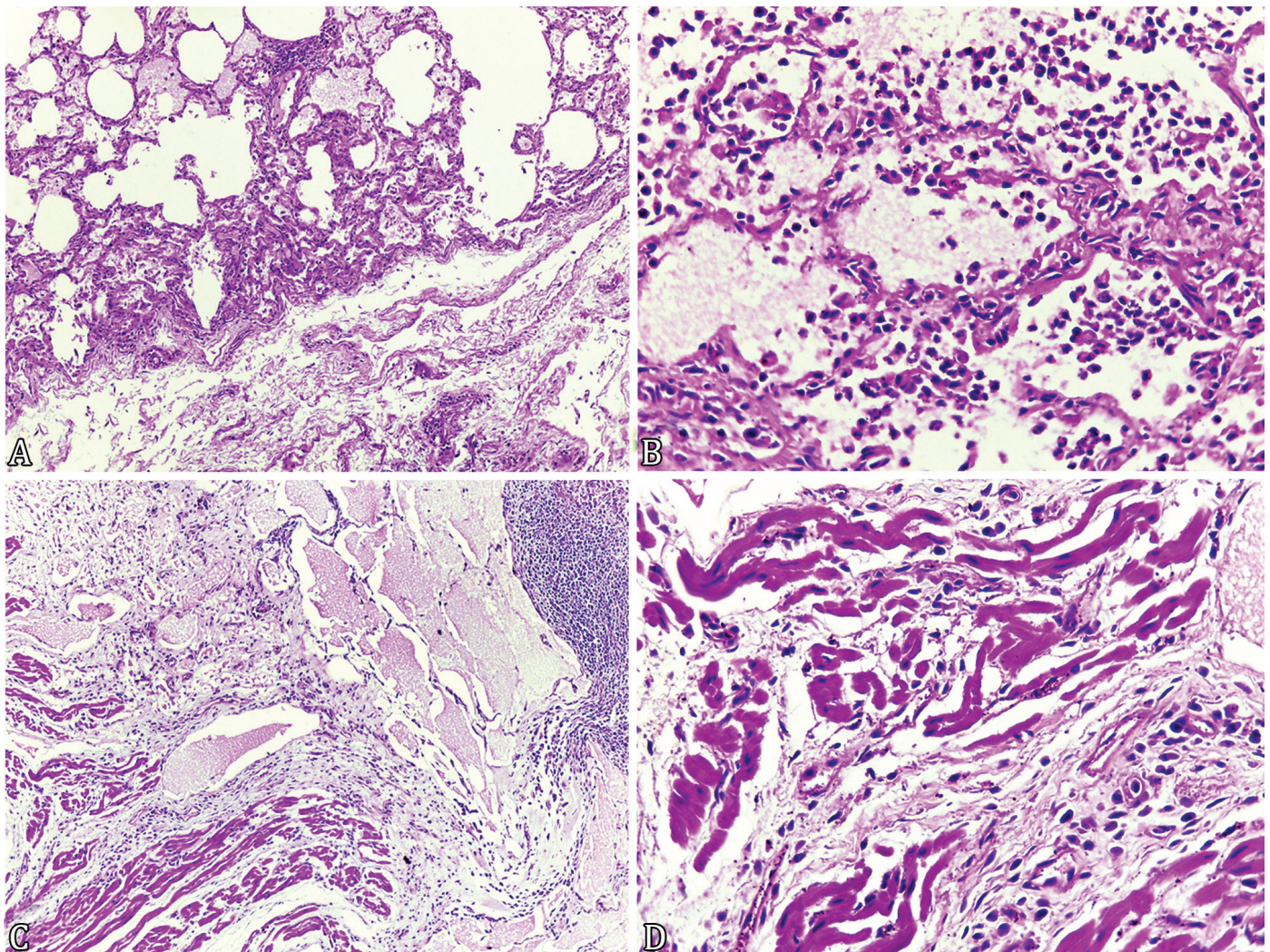


Fig.3. Histopathological aspects of Glässer's disease in swine. (A) Pleuropneumonia, characterized by pleural thickening with moderate presence of inflammatory fibrin-purulent infiltrate and pulmonary parenchyma with multifocal areas of intense neutrophilic infiltrate. HE, obj.10x. (B) Magnification of the last picture. Note in the alveolar lumen the inflammatory exudate composed by cellular debris, neutrophils, lymphocytes, and macrophages. Hyperplasia of type II pneumocytes is also observed. HE, obj.40x. (C) Fibrinous pericarditis. Note the high amount of fibrin and abundant inflammatory infiltration of neutrophils, histiocytes and lymphocytes replacing the subjacent cardiomyocyte layer. HE, obj.10x. (D) Cardiomyocytes are swollen with pyknotic nuclei and presents hyper eosinophilic cytoplasm. Note the cells interspersed by fibrin and large amount of macrophages. HE, obj.40x.

lymphocytes (Fig.3C). Multifocally, subepicardial cardiac myocytes were swollen and had loss of cross striations, pyknotic nuclei and hypereosinophilic cytoplasm (Fig.3D). Aggregates of eosinophilic finely beaded to fibrillar material were also common. The heart lesions were generally moderate to severe. In the brain, a mild infiltrate of lymphocytic and plasmatic cells were observed into under the leptomeninges in two cases. In the liver, kidney, and spleen, the main lesions consisted in congestion and admixed inflammatory infiltration, mainly composed of neutrophils, lymphocytes, and plasma cells.

Real-time PCR amplified *Haemophilus parasuis* *infB* gene in all samples analyzed, confirming the presence of *H. parasuis* in all samples analyzed from those three outbreaks, mainly in the lungs. In two cases, from piglets showing incoordination *H. parasuis* was identified in the brain. Additionally, in one of four samples analyzed, the genome of *Mycoplasma hyopneumoniae* was also found (Table 1).

DISCUSSION

The amplification of *infB* of *Haemophilus parasuis* genome through the real-time PCR described herewith indicates the circulation of this bacteria in swine herds in all regions of State of Pernambuco (Coastal, Forest, Agreste, and Sertão Zones). Until to date, there were no reports concerning the molecular diagnosis and descriptions of the epidemiology and the clinical-pathological aspects of the disease in northeastern Brazil. This lack of information could be occurring because GD remains unknown or the outbreaks are far from the influence of veterinary laboratories of diagnosis. There is also a lack of information about the occurrence of GD in the North region of Brazil. However in the states of the South, Southeast and Central-Western of the country this disease is well documented (Moreno et al. 2011, Teixeira et al. 2011, Espíndola 2017).

H. parasuis strains are heterogeneous in phenotypic and genotypic traits, including virulence. Strains are classified into 15 serovars. Variants 1, 5, 10, 12, 13 and 14 are classified as high virulence; 2, 4, 8 and 15 cause polyserositis being moderately virulent and serovars 3, 6, 7, 9 and 11 are considered non-virulent (Kielstein & Rapp-Gabrielson 1992). In this study, the isolation of serovars from outbreaks of the State of Pernambuco could not be performed. However, the most common variants worldwide are 4, 5, 12 and 13 (Rapp-Gabrielson et al. 1997, Rafiee & Blackall 2000, Cai et al. 2005). And in a recent study regarding molecular serotyping of clinical strains of *H. parasuis* from outbreaks in Brazil, serovars 4, 5 and 1 were described as most important in the country, comprising 70% of the isolates. In this same study, non-typeable strains were the second

most prevalent group of field strains (Espíndola et al. 2019). Considering this, additional studies in Northeastern Brazil should be made with the proposal to identify such strains. Thus, appropriate bacterin vaccines can be developed and distributed for the prevention of infection.

The clinical picture observed in the pigs from outbreaks of Pernambuco consisted mainly of petechial hemorrhages on the skin, high fever, respiratory distress, and neurological signs. In some cases, for inexperienced professionals, these clinical signs could be similar to those observed in classical swine fever and Aujeszky's disease (Brockmeier et al. 2002, Kim et al. 2002, Cai et al. 2005, Aragon et al. 2012), which are of compulsory notification to the sanitary governmental agencies. It is important to remember that the northeastern Brazil region recently had some outbreaks of classical swine fever. So, the veterinarians should be alert to the clinical and pathological differences between those diseases, mainly to make the correct decision when identifying an outbreak, because GD is not in the MAPA'S notification list (normative instruction no. 50).

The main lesions observed in GD described here, consisted in fibrinosuppurative pleuropneumonia, epicarditis and subepicardial fibrinous myocarditis. In two occasions mild meningitis was reported, and arthritis was not observed. On the other hand, although easily recognized, these typical lesions of polyserositis in nursery piglets may be caused by different bacteria (Olvera et al. 2009). For this reason, *Actinobacillus pleuropneumoniae*, *Actinobacillus suis*, *Streptococcus suis*, *Erysipelothrix rhusiopathiae*, *Pasteurella multocida* and *Mycoplasma hyorhinis* should be considered in the differential diagnosis of GD. Additionally, the occurrence of porcine reproductive and respiratory syndrome virus (PRRSV), porcine circovirus type 2 (PCV2), and influenza virus should be investigated because those virus also cause immunosuppressive conditions and allows *H. parasuis* strains that are usually restricted to the respiratory tract to invade other systems (Brockmeier et al. 2002, Kim et al. 2002, Cai et al. 2005, Olvera et al. 2009, Aragon et al. 2012).

On those outbreaks reported in Pernambuco, *M. hyorhinis* was also identified in one sample, but considering the low sanitary status of the herds is reasonable to assume that other pathogens could be implicated into the onset of these outbreaks. Other ancillary exams were not performed because considering that pigs with typical clinical signs such as growth retardation and a rough coat have a poor prognosis (Nedbalcova et al. 2006) and the high mortality rate on those properties, the measure adopted was the sanitary void.

Antibiotic treatment remains an essential control measure in the face of severe outbreaks of *H. parasuis* systemic infection.

Table 1. Laboratorial real-time PCR results from swine with clinical signs of Glässer's disease in Pernambuco

Sample	Outbreak location	<i>H. parasuis</i>	Tissue	<i>M. hyopneumoniae</i>	Tissue	PCV-2*	Tissue
1	C. de Santo Agostinho	+	Lung	NP**	NP	-	Lung
2	C. de Santo Agostinho	+	Lung	NP	NP	-	Lung
3	Paudalho	+	Lung	+	Lung	NP	NP
4	Paudalho	+	Lung	-	Lung	NP	NP
5	Paudalho	+	SNC	-	NP	NP	NP
6	Exu	+	SNC	-	NP	NP	NP
7	Exu	+	Lung	-	Lung	NP	NP
8	Exu	+	Lung	-	Lung	NP	NP

*PCV-2 = Porcine circovirus type 2, **NP = not performed.

However, antibiotic susceptibility profiles are variable in different countries and reflect the election of drugs used in each region (Aragon et al. 2012). For Brazilian strains, a study showed that field isolates were highly resistant to gentamicin, bacitracin, lincomycin and tiamulin, but sensitive to ampicillin, clindamycin, neomycin, penicillin, danofloxacin and enrofloxacin. However, a susceptibility test prior to antibiotic therapy during GD outbreaks should be considered by veterinarians (Miani et al. 2017). Particularly for population-level prophylaxis, the emphasis should be on vaccination strategies to prevent systemic infection and mortality combined with good biosecurity practices (Aragon et al. 2012, Luning et al. 2015).

CONCLUSION

In this study, epidemiological data, clinical signs, macroscopic, microscopic lesions, and amplification of *infB* gene of *Haemophilus parasuis* through real-time PCR confirms the presence of Glässer's disease in swine in the Northeast region of Brazil. Further studies should be conducted to identify the serotypes that circulate in this region.

Acknowledgments.- To the "Coordenação de Aperfeiçoamento de Pessoal de Nível Superior" (CAPES), Finance Code 001, and "Conselho Nacional de Desenvolvimento Científico e Tecnológico" (CNPq), Process 304804/2018-5, for granting the necessary financial support for the development of this study.

Conflict of interest statement.- The authors declare no conflicts of interest.

REFERENCES

- Amano H., Shibata M., Kajio N. & Morozumi T. 1994. Pathologic observations of pigs intranasally inoculated with serovars 1, 4 and 5 of *Haemophilus parasuis* using immunoperoxidase method. *J. Vet. Med. Sci.* 56(4):639-644. <<https://dx.doi.org/10.1292/jvms.56.639>> <PMid:7999883>
- Aragon V., Segales J. & Oliveira S. 2012. Glässer's disease, p.760-769. In: Zimmerman J.J., Karriker L.A., Ramirez A., Schwartz K.J. & Stevenson G.W. (Eds), *Diseases of Swine*. 10th. Wiley-Blackwell, Iowa.
- Aragon V., Segales J. & Tucker A.W. 2019. Glässer's disease, p.844-853. In: Zimmerman J.J., Karriker L.A., Ramirez A., Schwartz K.J., Stevenson G.W. & Zhang J. (Eds), *Diseases of Swine*. Wiley-Blackwell, New Jersey.
- Biberstein E.L. & White D.C. 1969. A proposal for the establishment of two new *Haemophilus* species. *J. Med. Microbiol.* 2(1):75-78. <<https://dx.doi.org/10.1099/00222615-2-1-75>> <PMid:5821848>
- Brockmeier S.L., Halbur P.G. & Thacker E.L. 2002. Porcine respiratory disease complex, p.231-258. In: Brogden K.A. & Guthmiller J.M. (Eds), *Polymicrobial Diseases*. Washington, ASM Press.
- Brockmeier S.L., Register K.B., Kuehn J.S., Nicholson T.L., Loving C.L., Bayles D.O., Shore S.M. & Phillips G.J. 2014. Virulence and draft genome sequence overview of multiple strains of the swine pathogen *Haemophilus parasuis*. *PLoS One* 9(8):e103787. <<https://dx.doi.org/10.1371/journal.pone.0103787>> <PMid:25137096>
- Cai X., Chen H., Blackall P.J., Yin Z., Wang L., Liu Z. & Jin M. 2005. Serological characterization of *Haemophilus parasuis* isolates from China. *Vet. Microbiol.* 111(3/4):231-236. <<https://dx.doi.org/10.1016/j.vetmic.2005.07.007>>
- Dickerman A., Aloka A.B. & Inzana T.J. 2020. Phylogenomic analysis of *Haemophilus parasuis* and proposed reclassification to *Gaesserella parasuis*, gen. nov. comb. nov. *Int. J. Syst. Evol. Microbiol.* 70(1):180-186. <<https://dx.doi.org/10.1099/ijsem.0.003730>> <PMid:31592757>
- Dubosson C.R., Conzelmann C., Miserez R., Boerlin P., Frey J., Zimmermann W., Häni H. & Kuhnert P. 2004. Development of two real-time PCR assays for the detection of *Mycoplasma hyopneumoniae* in clinical samples. *Vet. Microbiol.* 102(1/2):55-65. <<https://dx.doi.org/10.1016/j.vetmic.2004.05.007>> <PMid:15288927>
- Espíndola J.P. 2017. Determinação dos sorovares de *Haemophilus parasuis* relacionados com a doença de Glässer no Brasil. Master's Dissertation, Universidade de Passo Fundo, Passo Fundo. 56p.
- Espíndola J.P., Balbinott N., Gressier L.T., Machado G., Klein C.S., Rebelatto R., Martín C.B.G., Kreutz L.C., Schryvers A.B. & Frandoloso R. 2019. Molecular serotyping of clinical strains of *Haemophilus (Graesserella) parasuis* brings new insights regarding Glässer's disease outbreaks in Brazil. *PeerJ* 7:e6817. <<https://dx.doi.org/10.7717/peerj.6817>> <PMid:31198621>
- Gerveno J.M.C., Perez D.R., Blanco P.G., Jimenez W.L.G., Molino M.G., Llarío P.F., Salcedo J.H.M. & Gordo L.J.G. 2013. Fatal infection due to *Haemophilus parasuis* in a young wild boar (*Sus scrofa*). *J. Vet. Diagn. Invest.* 25(2):297-300. <<https://dx.doi.org/10.1177/1040638713479348>> <PMid:23512924>
- Holtkamp D., Rottó H. & Garcia R. 2007. Swine news newsletter 30:4.
- Kielstein P. & Rapp-Gabrielson V.J. 1992. Designation of 15 serovars of *Haemophilus parasuis* on the basis of immunodiffusion using heat-stable antigen extracts. *J. Clin. Microbiol.* 30(4):826-865. <<https://dx.doi.org/10.1128/JCM.30.4.862-865.1992>> <PMid:1572971>
- Kim J., Chung H.K., Jung T., Cho W.S., Choi C. & Chae C. 2002. Postweaning multisystemic wasting syndrome of pigs in Korea: prevalence, microscopic lesions and coexisting microorganisms. *J. Vet. Med. Sci.* 64(1):57-62. <<https://dx.doi.org/10.1292/jvms.64.57>> <PMid:11853147>
- Little T.W.A. 1970. *Haemophilus parasuis* infection in pigs. *Vet. Rec.* 87:399-402.
- Luning P., Kireziova K., Hagelaar G., Rovira J., Uyttendaele M. & Jacxsens L. 2015. Performance assessment of food safety management systems in animal-based food companies in view of their context characteristics: a European study. *Food Control* 49:11-22. <<https://dx.doi.org/10.1016/j.foodcont.2013.09.009>>
- Miani M., Lorenson M.S., Guizzo J.A., Espíndola J.P., Rodríguez-Ferri E.F., Gutiérrez-Martín C.B., Kreutz L.C. & Frandoloso R. 2017. Antimicrobial susceptibility patterns of Brazilian *Haemophilus parasuis* field isolates. *Pesq. Vet. Bras.* 37(11):1187-1192. <<https://dx.doi.org/10.1590/s0100-736x2017001100001>>
- Møller K. & Kilian M. 1990. V factor-dependent members of the family Pasteurellaceae in the porcine upper respiratory tract. *J. Clin. Microbiol.* 28(12):2711-2716. <<https://dx.doi.org/10.1128/JCM.28.12.2711-2716.1990>> <PMid:2280002>
- Møller K., Andersen L.V., Christensen G. & Kilian M. 1993. Optimization of the detection of NAD dependent Pasteurellaceae from the respiratory tract of slaughterhouse pigs. *Vet. Microbiol.* 36(3/4):261-271. <[https://dx.doi.org/10.1016/0378-1135\(93\)90093-m](https://dx.doi.org/10.1016/0378-1135(93)90093-m)> <PMid:8273273>
- Moreno L.Z., Castilla K.S., De Gobbi D.D., Coutinho T.A., Ferreira T.S. & Moreno A.M. 2011. ERIC-PCR genotypic characterization of *Haemophilus parasuis* isolated from Brazilian swine. *Braz. J. Microbiol.* 42(4):1420-1426. <<https://dx.doi.org/10.1590/S1517-83822011000400025>>
- Nedbalcova K., Satran S., Jaglic Z., Ondriasova R. & Kucerova Z. 2006. *Haemophilus parasuis* and Glässer's disease in pigs: a review. *Vet. Med.* 51(5):168-179.
- Oh S.S., Chu J., Park S.H., Park C.S., Kim M.C. & Jun M.H. 2006. Genetic characterization of porcine circovirus type 2 detected from the pigs in commercial swine farms in Korea. *J. Bacteriol. Virol.* 36(3):175-183. <<https://dx.doi.org/10.4167/JBV.2006.36.3.175>>
- Oliveira S. & Pijoan C. 2004. *Haemophilus parasuis*: new trends on diagnosis, epidemiology and control. *Vet. Microbiol.* 99(1):1-12. <<https://dx.doi.org/10.1016/j.vetmic.2003.12.001>> <PMid:15019107>
- Olvera A., Ballester M., Nofrarías M., Sibila M. & Aragon V. 2009. Differences in phagocytosis susceptibility in *Haemophilus parasuis* strains. *Vet. Res.* 40(3):24-40. <<https://dx.doi.org/10.1051/vetres/2009007>> <PMid:19239855>
- Olvera A., Pina S., Macedo N., Oliveira S., Aragon V. & Bensaid A. 2012. Identification of potentially virulent strains of *Haemophilus parasuis* using a multiplex

- PCR for virulence associated autotransporters (vitA). *Vet. J.* 191(2):213-218. <<https://dx.doi.org/10.1016/j.tvjl.2010.12.014>> <PMid:21247786>
- Rafiee M. & Blackall P.J. 2000. Establishment, validation and use of the Kielstein-Rapp-Gabrielson serotyping scheme for *Haemophilus parasuis*. *Aust. Vet. J.* 78(3):172-174. <<https://dx.doi.org/10.1111/j.1751-0813.2000.tb10586.x>> <PMid:10860155>
- Rapp-Gabrielson V.J., Gordon J.K., Jeffrey T.C. & Stephen K.M. 1997. *Haemophilus parasuis*: immunity in swine after vaccination. *Vet. Med.* 92(1):83-90.
- Teixeira M.L., Kuchiishi S.S. & Brandelli A. 2011. Isolation of *Haemophilus parasuis* from diagnostic samples in the south of Brazil. *Braz. J. Vet. Pathol.* 4(2):122-125.
- Turni C., Pyke M. & Blackall P.J. 2009. Validation of a real time PCR for *Haemophilus parasuis*. *J. Appl. Microbiol.* 108(4):1323-1331. <<https://dx.doi.org/10.1111/j.1365-2672.2009.04526.x>> <PMid:19778350>
- Vengust G., Valencak Z. & Bidovec A. 2006. A serological survey of selected pathogens in wild boar in Slovenia. *J. Vet. Med. Series B* 53(1):24-27. <<https://dx.doi.org/10.1111/j.1439-0450.2006.00899.x>> <PMid:16460352>
- Zanella J.R.C., Mores N. & Barcellos D.E.S.N.D. 2016. Principais ameaças sanitárias endêmicas da cadeia produtiva de suínos no Brasil. *Pesq. Agropec. Bras.* 51(5):443-453. <<https://dx.doi.org/10.1590/S0100-204X2016000500004>>