



Welfare and locomotor system disorders in active draft horses (cart horses)¹

Vivian C.M. Prado^{2*} , Maria Cristina F.N.S. Hage²  and Renata G.S. Dória² 

ABSTRACT.- Prado V.C.M., Hage M.C.F.N.S & Dória R.G.S. 2019. **Welfare and locomotor system disorders in active draft horses (cart horses).** *Pesquisa Veterinária Brasileira* 39(12):942-948. Departamento de Medicina Veterinária, Faculdade de Zootecnia e Engenharia de Alimentos, Universidade de São Paulo, Avenida Duque de Caxias Norte 225, Pirassununga, SP 13635-900, Brazil. E-mail: vivian.cmprado@gmail.com

Horses performing tasks is a common scene in urban centers, evidenced by the significant number of animals pulling carts along the streets (cart horses). Despite the rising concern of the population for animal welfare, as well as the creation of laws that prohibit traction activity in several Brazilian municipalities, these attitudes must be based on the impact of such activity on equine health. Locomotor system disorders are commonly observed in animals of this species, and become even more frequent when they are submitted to unhealthy working conditions. In this context, we conducted a survey on locomotor system disorders in 11 active draft horses. To this end, we performed lameness assessments and radiographic and ultrasound examinations. Information on management regarding the horses' hooves, type of harness used, and type of work performed was also obtained through the application of questionnaires to the owners. The collected data showed that, although most of the animals in the study presented critical orthopedic conditions, they were not treated and the horses did not rest for adequate time. We observed that the disorders, which are often chronic, may be directly associated with incorrect management of the animals. We emphasize the importance to disseminate information that values the welfare of traction animals in order to tackle mistreatment.

INDEX TERMS: Animal well-being, locomotor system, draft horses, cart horses, lameness assessment, horses.

RESUMO.- [Bem-estar e afecções do aparelho locomotor de equinos de tração (carroceiros) em atividade.] Cavalos desempenhando tarefas para o homem é ainda uma cena marcante nos centros urbanos, evidenciada pela grande quantidade de animais que traçam carroças pelas ruas (carroceiros). Apesar da crescente preocupação da população com o bem estar animal, assim como a criação de leis que proíbem a atividade de tração em diversos municípios brasileiros, é imprescindível que estas atitudes estejam embasadas no impacto de tal atividade sobre a saúde dos equinos. Nesta espécie, afecções do aparelho locomotor são comuns, tornando-se ainda mais frequentes quando os animais são submetidos a condições insalubres de trabalho.

Por conseguinte, este estudo promoveu um levantamento das afecções que acometem o aparelho locomotor de 11 equinos de tração em atividade, por meio de exames de claudicação, radiográficos e ultrassonográficos. Informações sobre manejo realizado pelos proprietários quanto aos cascos de seus animais, tipos de arreios utilizados e tipo de trabalho ao qual eram submetidos foram obtidas através de questionários. Verificou-se ao relacionar dados coletados, que a maioria dos animais do estudo apresentava afecções ortopédicas importantes, e que, entretanto, não eram tratados ou mantidos em repouso por tempo adequado. Observou-se que as afecções encontradas, muitas vezes crônicas, podem ter relação direta com o manejo incorreto dos animais, e ressalta-se a importância da disseminação de informações que prezem pelo bem estar do animal de carroça, a fim de combater maus tratos nesta categoria animal.

TERMOS DE INDEXAÇÃO: Bem estar animal, afecções de aparelho locomotor, equinos de tração, carroceiros, exame de claudicação, cavalos.

¹ Received on June 10, 2019.

Accepted for publication on July 17, 2019.

Undergraduate Research Scholarship by FAPESP process no. 2015/12009-8.

² Departamento de Medicina Veterinária (DMV), Faculdade de Zootecnia e Engenharia de Alimentos (FZEA), Universidade de São Paulo (USP), Avenida Duque de Caxias Norte 225, Pirassununga, SP 13635-900, Brazil.

*Corresponding author: vivian.cmprado@gmail.com

INTRODUCTION

Since their domestication, horses have been used by humankind in various types of work and athletic activities. They are often demanded beyond their natural limits, despite growing awareness and claims for improvement in equine welfare (Fraser 2001, Goodship & Birch 2001). In particular, horses used as traction forces for carts laden with rubbish and rubble produced by the population within urban centers should be monitored for their well-being and health, as they still represent an essential work tool in society (Rezende 2004).

The athletic characteristics presented by an animal are the product of several factors to which it is subjected, such as climate, management, training, type of harness, work surface and genetics (Jones 1987), and the performance of animals also reflects the excellent condition of its locomotor apparatus (Maranhão et al. 2006). Locomotor system disorders were one of the leading clinical findings in the draft horses involved in recent animal studies conducted in Pakistan (Hameed et al. 2016) and Ethiopia (Mekonnen & Channe 2016), in which almost all of the animals studied, active traction mules, presented limitations of use in relation to their orthopedic disorders.

Inflammatory and degenerative orthopedic disorders lead to functional disability in horses, reducing their performance, which combined with the high costs of therapeutic procedures, impact mainly the poorest population, who cannot afford veterinary assistance to their horses, considered an essential work tool (De Bari et al. 2001, Souza 2006). Although the quality of trimming and shoeing is vital in active horses, in the case of draft horses (cart horses), a high prevalence of foot imbalance has previously been demonstrated, probably due to inadequate techniques used in the manufacture of rubber horseshoes, whose non-uniform thickness causes unequal distribution of limb forces during movement (Maranhão et al. 2007). In addition, the excess load to which a horse is subjected causes poor weight distribution between the limbs and hooves, favoring the onset of locomotor system disorders, since there is no adequacy of traction vehicles to the horse's gait (Faria et al. 2014, Mariz et al. 2014).

Currently, the use of draft horses in rural areas as an economic alternative has been widely discussed (Maranhão et al. 2006), but there are few reports on the use of these animals in the urban environment the literature, and the existing ones do not assess the correlation between the health and working conditions of these animals. Rio de Janeiro was the first Brazilian state to prohibit the use of animal traction vehicles in urban centers (State Law no. 7,194; January 7, 2016) (Rio de Janeiro 2016). Other localities have also followed the same principle, prohibiting, regulating or reducing the number of animal traction vehicles through legislation such as Municipal Law no. 11,468 of December 29, 2011 (Londrina 2011), Municipal Law no. 10,531 of September 10, 2008 (Porto Alegre 2008), Municipal Law no. 13,908 of December 19, 2011 (Curitiba 2011), Municipal Law no. 8,122 of October 17, 2018 (Araçatuba 2018), Municipal Law no. 9,411 of December 18, 2018 (Belém 2018), among others.

This study aimed to evaluate the locomotor system disorders in active draft horses (cart horses) in the municipality of Pirassununga, Sao Paulo state, and observe their relationship with the type of work performed and trimming, shoeing and harnessing in this population with a concern for animal welfare.

MATERIALS AND METHODS

The study sample was composed of 11 lame horses, six geldings and five mares, aged 15 years (± 7.28) on average, with mean weight of 331kg (± 28.87), which performed physical activity pulling carts in the municipality of Pirassununga, Sao Paulo state, Brazil. All animals were linked to the "Projeto Carroceiro" (Wagoner Project) of the "Faculdade de Zootecnia e Engenharia de Alimentos", "Universidade de São Paulo" (FZEA-USP).

After conducting physical examination and lameness assessment, anamnesis data were collected through questionnaires applied to the horses' owners. Radiographic and ultrasound examinations of the musculoskeletal structures were performed, as indicated by the lameness examination. All lameness assessments were performed by the same veterinarian with experience in the field. Diagnostic imaging examinations were performed by an experienced examiner (M.C.F.N.S.H.) and observed by an inexperienced evaluator (V.C.M.P.).

The lameness examination was performed according to Stashak (2002), and consisted of observation of the animal at rest and during exercise, palpation and systematic manipulation of the limbs, followed by flexion tests and perineural anesthetic blocks. Any changes in anatomy, painful response to palpation/manipulation, as well as worsening of lameness in response to flexion tests were recorded. The radiographs were taken as recommended by O'Brien (2006) and were obtained using 100mA, 90kV portable X-ray equipment with a rotating ampoule. Ultrasonography was performed according to the examination protocol described by Genovese et al. (1986) using an Esaote® MyLab™ ClassC Vet device equipped with a high-frequency linear transducer (LA 435 6-18MHz).

The questionnaire applied to owners included questions regarding the type of work performed by the animal, traction load, work frequency, hoof handling such as trimming and shoeing (who harnesses the horse, how often it is harnessed, and what material is used in shoeing), and type harness (neck collar or breast strap) used. Information on previous lameness and treatment was also collected.

RESULTS

All horses examined were lame and fully performing working activities. Ten different locomotor system disorders were identified and divided by similarity into five groups: Group 1, tissue lesions such as tendonitis and firing, effusion and adhesion of the sheath; Group 2, degenerative joint disease (DJD) and joint effusion; Group 3, conditions caused by excess load on the metacarpophalangeal and/or metatarsophalangeal joints, such as hyperextension and proximal sesamoid bone lesions; Group 4, fractures; Group 5, laminitis with distal phalanx rotation.

The following percentages of locomotor system disorders were observed: 63.6% (7/11), Group 1; 45.4% (5/11), Group 2; 45.4% (5/11), Group 3; 18.2% (2/11), Group 4; 9% (1/11), Group 5. Thus, 36.4% of the animals (4/11) were included in one lesion group, 45.4% (5/11) were in two injury groups, and 18.2% (2/11) were in three lesion groups (Table 1; Fig.1).

None of the owners claimed to notice lameness, medicate their animals, or dismiss them from work. The vast majority of the owners associated lameness with the type of gait of their animals.

Among the draft horse owners that responded to the questionnaire (n=9), 22.2% (2/9) did not provide their animals with any type of trimming or shoeing and 77.8% (7/9) of them did. According to the owners, 44.4% (4/9)

Table 1. Equine locomotor system disorders according to group and diagnostic tool used (ultrasound or x-ray)

Animal	Group	Diagnostic tool	Locomotor system disorder
A*	1/3	US	(TLs) Chronic tendonitis reactivated in flexor tendons. (RTL) Acute tendonitis in SDFT. Periostitis in MPSB. (LTL) Adhesion between SDFT and tendon sheath with sheath effusion.
B	1/3	XR US	(LPL) LPSB and MPSB periostitis. (LPL) Chronic tendonitis reactivated in flexor tendons and sheath effusion.
C	1/2/4	XR US	(LPL) Tibia avulsion fracture. Degenerative joint disease (DJD) in intertarsal joints. (RTL) Chronic tendonitis reactivated in flexor tendons and sheath effusion. Chronic tendonitis in DDFT. (LTL) Chronic tendonitis reactivated in SDFT. Annular ligament desmitis. (RPL) Adhesion between SDFT and DDFT and tendon sheath effusion. (LPL) Adhesion between SDFT and DDFT and tendon sheath effusion. Annular ligament desmitis.
D	2	XR	(LPL) Osteophyte in the insertion of the medial collateral ligament of the proximal interphalangeal joint (DJD) and joint effusion.
E	2	XR	(RPL) Osteophyte in the 3rd metatarsal bone (DJD).
F*	5	XR	(LTL, RPL) Rotating laminitis of the 3rd phalanx.
G	1	US	(RTL) Laceration of the radial carpal extensor tendon and carpal sheath, with sheath effusion.
H	1/3	US	(RPL) Acute tendonitis in SDFT and tendon sheath effusion. Periostitis in LPSB and MPSB. (LPL) Acute tendonitis in SDFT and tendon sheath effusion.
I	1/2	XR US	(LPL) Osteophyte in proximal interarsal joint (DJD) and joint effusion. (RTL) Chronic tendonitis reactivated in flexor tendons with sheath effusion. Annular ligament desmitis.
J	2/3/4	XR	(LTL) Osteophytes in the insertion region of the 1st phalanx sesamoid ligaments (DJD). Flexural deformity (hyperextension) of the metacarpophalangeal and distal interphalangeal joints. Periostitis in the 3rd and 4th metacarpal bones. (RTL) Periosteal reaction in the radius, 3rd metacarpal, ulnar, intercarpal and carpal bones (DJD). Joint effusion. (LPL) LPSB avulsion fracture. Flexural deformity (hyperextension) in the metatarsophalangeal joint.
K	1/3	US	(RTL) Chronic tendonitis reactivated in SDFT and DDFT. Ligament check desmitis. Periosteal reaction in MPSB. (LTL) Chronic tendonitis reactivated in flexor tendons. Periostitis in MPSB and LPSB.

* Animals whose owners did not respond to the questionnaire; 1 = tendonitis, desmitis, adhesion and effusion of the tendon sheath, 2 = degenerative joint disease and joint effusion, 3 = hyperextension and injuries to proximal sesamoid bones, 4 = fractures, 5 = laminitis, US = ultrasound, XR = x-ray, TLs = thoracic limbs, RTL = right thoracic limb, LTL = left thoracic limb, RPL = right pelvic limb, LPL = left pelvic limb, SDFT = superficial digital flexor tendon, DDFT = deep digital flexor tendon, MPSB = medial proximal sesamoid bone, LPSB = lateral proximal sesamoid bone, DJD = degenerative joint disease.

of the draft horses underwent only manual trimming. The horseshoes, made from truck rubber tires, were fixed to the hooves of the horses by their owners, using nails and a hammer. The handmade horseshoes were fixed back into place when they detached from the hooves, and were replaced with new ones only when thoroughly worn. Also according to the owners, 33.3% (3/9) of the draft horses were provided with proper farrier trimming and conventional metal horseshoes, which were refit when detached from the hooves and replaced when worn. All owners reported that in the time interval between horseshoe (rubber or metal) detachment and refit or replacement, the animals remained active, with some hooves shod and others not.

Anamnesis showed that the animals worked 29h (± 16.1 h) per week (five working days) on average. Percentage distribution by weekly working hours was as follows: 22.2% (2/9), 10h; 11.1% (1/9), 20h; 22.2% (2/9), 30h; 22.2% (2/9), 40h; 22.2% (2/9), over 40 h. Common loads carried by the animals included rubble (6/9, 66.7%) and people (3/9, 33.3%). Regarding the type of harness, 77.8% (7/9) used neck collar and 22.2% (2/9) used breast strap.

DISCUSSIONS

According to the animals' history, lameness assessments and images examinations, it was possible to identify different locomotor disorders in the draft horses of this study, and they could be associated with the data obtained on the type of work performed, type of harness used, and hoof care. It is worth noting that all animals were under full work activity despite the disorders that affected them - a finding also observed in similar studies (Hameed et al. 2016, Mekonnen & Channe 2016).

Tendonitis, especially chronic tendonitis, was the disease most commonly found among the animals, accounting for 63.6% (7/11) of those examined, suggesting that acute tendon injuries were not correctly treated and the rest period was not respected, making the injuries chronic. Resting for at least two months is recommended for the treatment of horses with tendonitis at any stage of evolution, according to Thomassian (2005). Even with traditional therapies, the healing of a tendon injury can extend over long periods of a horse's life until it is resolved entirely (Maia 2008). Tendon injuries are justified in the animals under study, as they are associated with great efforts (McIlwraith 2006), as found by

the questionnaires, which also showed that the work of these animals is intense, pulling heavy loads for long hours daily (6 ± 3 h per day, five days per week, on average), as observed by Pritchard et al. (2005).

Synovial fluid effusion in tendon sheaths was associated with lesions in equine tendon or ligament structures, characterizing tenosynovitis, diagnosed in 45.4% (5/11) of the evaluated animals. This may be the result of injuries caused by

excessive exercise that sometimes causes hyperextension of the metacarpo/metatarsophalangeal joints, especially when they are subjected to excess load (Gomide et al. 2004), as in the case of the animals under study. Likewise, as a consequence of tendon injuries, 18.2% (2/11) of adhesion between tendons and adjacent structures and 9% (1/11) of annular firing were found, with pain and severe lameness (Dik et al. 1995, McIlwraith 2006). Treatment of these conditions is usually

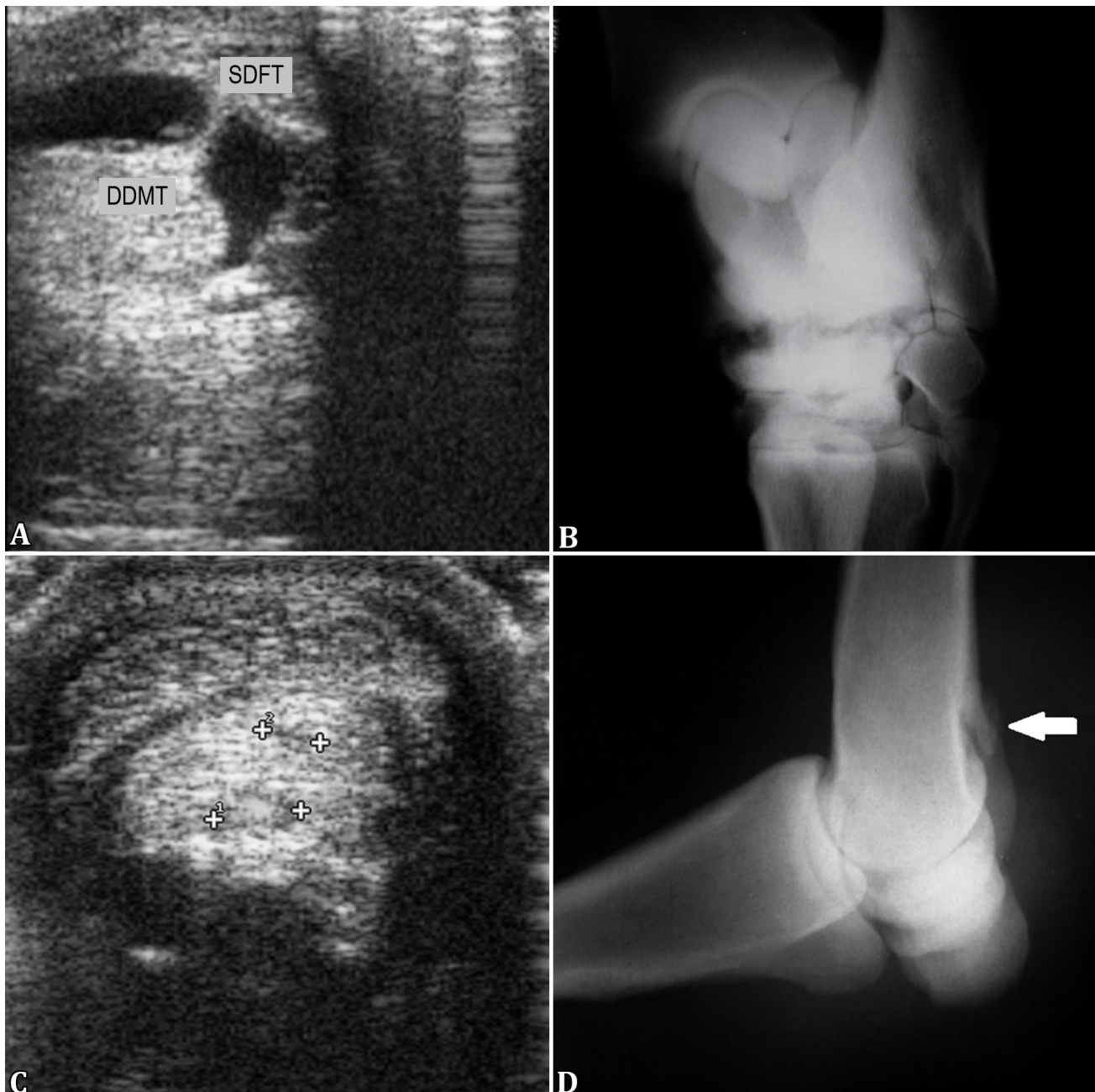


Fig.1. Illustration of injuries found in the locomotor system of the draft horses studied. **(A)** Adhesion and effusion between the superficial digital flexor tendon (SDFT) and deep digital flexor tendon (DDFT) of the left pelvic limb, visualized in the transverse ultrasound image of the proximal plantar region. **(B)** Decrease in radiographic interline caused by osteolysis of the subchondral bone that composes the proximal and distal intertarsal joints, with adjacent sclerosis visualized in dorsolateral-plantaromedial radiograph. **(C)** Two chronic (inter-crossed) cross-sectional lesions in the DDFT of the right thoracic limb in the transverse ultrasound image. **(D)** Bone fragment with rounded contours (arrow) in the distal third of the 3rd left metatarsal bone, observed in lateral radiograph, suggestive of avulsion fracture of the lateral proximal sesamoid bone and flexural deformity in the metacarpophalangeal joint.

surgical, followed by intensive postoperative physiotherapy, which was not performed in any of the animals under study considering that they were active.

Lesions to the proximal sesamoid bones were found in 45.4% (5/11) of the animals under study, and an avulsion apex fracture of the proximal sesamoid bone and four other periosteal reactions in these bones were diagnosed at the point of insertion of the lateral and medial suspensory ligament branches. The suspensory apparatus consists of the suspensory ligament of the metacarpal bone and its branches, in addition to the proximal sesamoid bones and their ligaments (Denoix 1994). These structures are subject to injuries, mainly due to overload from exhaustive physical activities, such as pulling excess load (Pool & Meagher 1990), as well as hoof imbalance (Gibson & Steel 2002). If treated, apex fractures of the proximal sesamoid bones may have a good prognosis (Woodie et al. 2000), as well as firing of the lateral and medial branches of the suspensory ligament, usually associated with periostitis at its insertion site in the proximal sesamoid bones (Gibson & Steel 2002). However, in the animals of this study, no treatment had been performed, and they remained active.

As a consequence of local trauma, failure in joint stability and chronic osteoarthritis (McIlwraith 2002, Park 2014), it was possible to verify the presence of degenerative joint disease (DJD) in 54.5% (6/11) of the animals; this disorder is almost always associated with findings such as osteophytes, periosteal reaction, and joint effusion. Upright defects, angular and flexural deformities, unbalanced and firing sheath, and overweight or joint overload are the causes of DJD, which most often progresses to loss of joint function and pain (Veiga 2006). Considering the data obtained from the questionnaires, it is evident that the draft animals (cart horses) physically exercise under inadequate conditions, which resulted in the numerous injuries observed.

Laminitis was diagnosed in one animal, which presented 4 and 5 degree rotation in the distal phalanx of the left thoracic and right pelvic limbs, respectively. Pathogenesis of this condition involves mechanical overload of the hooves when subjected to intense impact from exercise on hard soil (Baxter 1994). This condition leads to intense pain, which makes it impossible for the animal to develop any physical activity with effort (O'Grady 2010). In this case, although the animal was limping, it was still active.

The data obtained showed that the pelvic limbs of the studied animals presented larger number of lesions (14) compared with the thoracic limbs (10). Thus, it is evident that there is greater stress on the pelvic limbs of draft horses, which are overloaded when they have to pull carts with heavy loads, because its center of balance is usually displaced closer to the thoracic limbs (Ross 2003, Moyer & Carter 2007). This fact corroborates the evidence that draft horses (cart horses) are submitting their locomotor system to activities that they are not physiologically adapted, predisposing the onset of injuries, which opposes ethical and animal welfare aspects.

As for trimming and shoeing, responses to the questionnaires showed that 66.7% of the horses were not submitted to the proper procedures and two animals worked without horseshoes. It is worth noting that handmade horseshoes manufactured by animal owners using tire rubber do not follow the basic principles of trimming and shoeing, which

consider the biomechanics of the locomotor system and hoof balance in order to minimize orthopedic injuries and lameness (Stashak et al. 2006). Owners claim they use this material, which can be easily obtained and handled, in order to prevent slipping on urban asphalt caused by lack of adherence of traditional metal horseshoes (Yxklinten 1996). These findings stress the need for studies addressing the benefits of trimming followed by shoeing with horseshoes made of rubber, respecting the anatomy and biomechanics of equine limbs.

Moreover, fitting with handmade horseshoes by owners who are unaware of hoof anatomy and shoeing techniques favors technical errors such as puncture wound, that is, perforation by misplaced nails in vascularized hoof tissue, which can lead to severe and potentially fatal conditions, such as tetanus (Cullinane et al. 1999).

It was also observed that the draft horses assessed lack periodic hoof trimming and had their horseshoes replaced much less frequently than recommended, which are factors that predispose orthopedic injuries because of growing unbalance of the hooves, compromising the movement of the animals (Stashak et al. 2006). Furthermore, there was the fact that the animals remained working with some hooves shod and others not when detachment occurred. Sporting animals with unbalanced hooves are predisposed to conditions such as arthritis, osteitis, desmitis and tendonitis due to irregular distribution of forces between bone, tendon, and ligament structures (Balch et al. 1995).

Although animals are used as a means of work, special attention is not paid to maintaining the health of the locomotor system, which is essential to prevent the occurrence of orthopedic injuries, ensuring the welfare of horses in service.

Assessment of the type of harness showed that the animals that used neck collar presented a larger number of orthopedic injuries (average of two conditions per animal) compared with those that used breast strap (average of 1.57 conditions per animal). According to Hovell (1998), a good harness is one that allows the animal to apply its full tractive force to itself, whether a neck collar or a breast strap. However, it is known that some types of equipment, such as neck collars, can be designed to compress the jugular veins of the animal, rendering ineffective in its function because it does not allow full utilization of the horse's tractive force (Proust 1991), which unnecessarily tries harder to perform its tasks. Therefore, the use of breast straps should be encouraged among wagoners.

Regarding working time, it was observed that most animals worked continuously and intensively 6 (± 3) hours per day on average, five days a week, and that 44% of them work 8 h a day or more, five days a week. This finding includes cart horses in the category of sport animals (Ross 2010), justifying hoof health care and use of proper harness, and emphasizes the need to evaluate the full load carried so that it is not excessive for the working time performed. Likewise, aspects such as adequate nutrition, body score, age, and hygiene of these draft horses should be considered and the type and time of work performed should be identified. This should be the individual suitability required for a group of animals to perform their activities, that is, the welfare of each animal, which would reflect in smaller occurrence of disorders, including orthopedic conditions.

Results of this study showed that most of the observed locomotor system disorders were associated with excessive physical effort, inadequate hoof management, and lack of early treatment of orthopedic conditions, that is, a lame animal should be immediately evaluated by a veterinarian, dismissed from its activities during treatment, and return to work only after discharge. This behavior would prevent acute disorders from becoming chronic and draft horses from working under pain and suffering, as evidenced in this study. Similarly, Ross (2010) reported the neglect of top-class horse owners and trainers, who often spare no competitions even when their horses clearly show lameness, reinforcing the enormous mental as well as physical strength that these animals should have in order to perform their tasks under non-ideal health conditions.

Horses with orthopedic injuries should not undergo intense and continuous work, as observed in this study. A horse in pain does not eat properly (Price et al. 2003), which favors weight loss and, consequently, decreased performance (Kronfeld 1993). This study highlights the need for improvements in the welfare of draft horses, which work inappropriately and are kept in service in poor health, negatively affecting their productivity. Prioritizing the welfare of these animals will considerably improve the quality of their work, leading to more significant revenue to their owners (Hameed et al. 2016).

Often, as governmental organizations are not structured to identify problems associated with animal traction, their data result unrepresentative or inadequate to actual animal conditions (Goe & McDowell 1980). We suggest that municipalities register and supervise wagoners in urban activity, and offer veterinary services that would be responsible for adequacy of the nutritional, sanitary and specific service capacity of each horse, as well as for offering medical care, authorizing the use of the animal only after discharge.

CONCLUSIONS

Traction horses (cart horses) perform daily physical activity even with major orthopedic injuries, especially chronic ones. Hard work associated with inadequate hoof management is the predisposing factor for the various orthopedic disorders found.

It is important to disseminate information that values the welfare of draft horses and emphasize the need of a competent veterinarian in the supervision of this activity in order to tackle common mistreatment to in this animal species.

Acknowledgments.- The authors are grateful to FAPESP (process no. 2015/12009-8) for the undergraduate research scholarship provided to the first author, and for the funding of this publication provided to the last author (process no. 2019/03193-0), to Paulo Henrique França (X-ray technician) for his assistance in performing the radiographic examinations, and to Mariana Sachi Invernizzi (resident in veterinary medicine) for the ultrasonographic examination of the animal identified as G in Table 1.

Conflict of interest statement.- The authors have no competing interests to declare.

REFERENCES

Araçatuba 2018. Dispõe sobre a utilização de veículos com tração animal no município e dá outras providências. Lei Municipal nº 8.122, de 17 de outubro de 2018, Legislação Municipal de Araçatuba, Araçatuba, SP.

- Balch O., Butler D., White K. & Metcalf S. 1995. Hoof balance and lameness: improper toe length, hoof angle, and mediolateral balance. *Comp. Contin. Educ. Pract. Vet.* 17(10):1275-1278.
- Baxter G.M. 1994. Acute laminitis. *Vet. Clin. N. Am., Equine Pract.* 10(3):627-662. <[http://dx.doi.org/10.1016/S0749-0739\(17\)30351-6](http://dx.doi.org/10.1016/S0749-0739(17)30351-6)>
- Belém 2018. Institui no município de Belém o programa de redução gradativa do número de veículos de tração animal, que circulam no trânsito em áreas urbanas, e dá outras providências. Lei Municipal nº 9.411, de 18 de dezembro de 2018, Belém, PA.
- Cullinane A.A., Bernard W., Duncan J.L., Smith I.M. & Timoney F. 1999. Infectious diseases, p.65-70. In: Higgins A.J. & Wright I.M. (Eds), *The Equine Manual*. W.B. Saunders, London.
- Curitiba 2011. Estabelece, no âmbito do município de Curitiba, sanções e penalidades administrativas para aqueles que praticarem maus-tratos aos animais e dá outras providências. Lei Municipal nº 13.908, de 19 de dezembro de 2011, Curitiba, PR.
- De Bari C., Dell'Accio F., Tylzanowski P. & Luyten F.P. 2001. Multipotent mesenchymal stem cells from adult synovial membrane. *Arthritis Rheum.* 44(8):1928-1942. <[http://dx.doi.org/10.1002/1529-0131\(200108\)44:8<1928::AID-ART331>3.0.CO;2-P](http://dx.doi.org/10.1002/1529-0131(200108)44:8<1928::AID-ART331>3.0.CO;2-P)> <PMid:11508446>
- Denoix J. 1994. Functional anatomy of tendons and ligaments in the distal limbs (manus and pes). *Vet. Clin. N. Am., Equine Pract.* 10(2):273-322. <[http://dx.doi.org/10.1016/S0749-0739\(17\)30358-9](http://dx.doi.org/10.1016/S0749-0739(17)30358-9)> <PMid:7987720>
- Dik K.J., Dyson S.J. & Vail T.B. 1995. Aseptic tenosynovitis of the digital flexor tendon sheath, fetlock and pastern annular ligament constriction. *Vet. Clin. N. Am., Equine Pract.* 11(2):151-162. <[http://dx.doi.org/10.1016/S0749-0739\(17\)30317-6](http://dx.doi.org/10.1016/S0749-0739(17)30317-6)> <PMid:7584732>
- Faria M.D., Santos M.A.M., Martins L.F.T., Gradela A., Pereira Neto J. & Bandeira C.G.C. 2014. Biometria podal de equídeos (*Equus* sp. Linnaeus, 1758) de tração. *Ciênc. Anim. Bras.* 15(2):220-227. <<http://dx.doi.org/10.1590/1809-6891v15i220318>>
- Fraser D. 2001. The 'new perception' of animal agriculture: legless cows, featherless chickens, and a need for genuine analysis. *J. Anim. Sci.* 79(3):634-661. <<http://dx.doi.org/10.2527/2001.793634x>> <PMid:11263823>
- Genovese R.L., Rantanen N.W., Hauser M.L. & Simpson B.S. 1986. Diagnostic ultrasonography of equine limbs. *Vet. Clin. N. Am., Equine Pract.* 2(1):145-226. <[http://dx.doi.org/10.1016/S0749-0739\(17\)30738-1](http://dx.doi.org/10.1016/S0749-0739(17)30738-1)> <PMid:3516322>
- Gibson K.T. & Steel C.M. 2002. Conditions of the suspensory ligament causing lameness in horses: tutorial article. *Equine Vet. Educ.* 14(1):39-50. <<http://dx.doi.org/10.1111/j.2042-3292.2002.tb00137.x>>
- Goe M.R. & McDowell R.E. 1980. *Animal Traction: guidelines for utilization*. Cornell International Agriculture Mimeograph No. 81, Cornell University, Ithaca, NY.
- Gomide L.M.W., Castro Netto A., Orozco C.A.G., Martins C.B., Ribeiro G., Sampaio R.C.L. & Lacerda Neto J.C. 2004. Alterações ultra-sonográficas em equinos com lesões crônicas distais do tendão flexor digital profundo e estruturas correlatas. *Braz. J. Vet. Res. Anim. Sci.* 41:260-261.
- Goodship A.E. & Birch H.L. 2001. Exercise effects on the skeletal tissues, p.227-250. In: Back W. & Clayton H. (Eds), *Equine Locomotion*. W.B. Saunders, London.
- Hameed A., Tariq M. & Yasin M.A. 2016. Assessment of welfare of working donkeys and mules using health and behavior parameters. *J. Agric. Sci. Food Technol.* 2(5):69-74.
- Hovell G.J.R. 1998. Welfare considerations when attaching animals to vehicles. *Appl. Anim. Behav. Sci.* 59(1/3):11-17. <[http://dx.doi.org/10.1016/S0168-1591\(98\)00116-6](http://dx.doi.org/10.1016/S0168-1591(98)00116-6)>
- Jones W.E. 1987. *Genética e Criação de Cavalos*. Roca, São Paulo. 666p.
- Kronfeld D.S. 1993. Starvation and malnutrition of horses: recognition and treatment. *J. Equine Vet. Sci.* 13(5):298-304. <[http://dx.doi.org/10.1016/S0737-0806\(07\)80253-X](http://dx.doi.org/10.1016/S0737-0806(07)80253-X)>

- Londrina 2011. Institui o código de posturas do município de Londrina. Lei Municipal nº 11.468, de 29 de dezembro de 2011, Londrina, PR.
- Maia L. 2008. Plasma rico em plaquetas no tratamento de tendinite em equinos: avaliação clínica, ultra-sonográfica e histopatológica. Master's Thesis, Universidade Federal de Viçosa, Viçosa. 78p.
- Maranhão R.P.A., Palhares M.S., Melo U.P., Rezende H.H.C. & Ferreira C. 2007. Avaliação biométrica do equilíbrio podal de equídeos de tração no município de Belo Horizonte. *Ciênc. Anim. Bras.* 8:297-305.
- Maranhão R.P.A., Palhares M.S., Melo U.P., Rezende H.H.C., Braga C.E., Silva Filho J.M. & Vasconcelos M.N.F. 2006. Afecções mais frequentes do aparelho locomotor dos equídeos de tração no município de Belo Horizonte. *Arq. Bras. Med. Vet. Zootec.* 58(1):21-27. <<http://dx.doi.org/10.1590/S0102-09352006000100004>>
- Mariz T.M.A., Escodro P.B., Dittrich J.R., Souza Neto M., Lima C.B. & Ribeiro J.S. 2014. Padrão biométrico, medidas de atrelagem e índice de carga de equídeos de tração urbana do município de Arapiraca, Alagoas. *Arch. Vet. Sci.* 19:1-8.
- McIlwraith C.W. 2002. Diseases of joints, p.459-594. In: Stashak T.S. (Eds), *Adam's Lameness in Horses*. 5th ed. Lippincott Williams and Wilkins, Philadelphia.
- McIlwraith C.W. 2006. Doenças das articulações, tendões, ligamentos e estruturas relacionadas, p.551-597. In: Stashak T.S. (Eds), *Claudicação em Equinos Segundo Adams*. 5ª ed. Roca, São Paulo.
- Mekonnen N. & Channe D. 2016. Management practices of working donkeys in urban and rural areas of Assosa District, Benishangulmuze region, Ethiopia. *World J. Agr. Sci.* 12(5):346-356.
- Moyer W.A. & Carter G.K. 2007. Diagnostic evaluation of equine foot, p.112-127. In: Floyd A.E. & Mansmann R.A. (Eds), *Equine Podiatry*. W.B. Saunders, St Louis. <<http://dx.doi.org/10.1016/B978-072160383-4.50012-8>>.
- O'Brien T.R. 2006. Radiologia de Equinos. Roca, São Paulo. 244p.
- O'Grady S.E. 2010. Farriery for chronic laminitis. *Vet. Clin. N. Am. Equine Pract.* 26(2):407-423. <<http://dx.doi.org/10.1016/j.cveq.2010.04.008>> <PMid:20699184>
- Park R.D. 2014. Diagnóstico por imagem parte I radiologia, p.174-177. In: Stashak T.S. (Eds), *Claudicação em Equinos Segundo Adams*. 5ª ed. Roca, São Paulo.
- Pool R.R. & Meagher D.M. 1990. Pathologic findings and pathogenesis of racetrack injuries. *Vet. Clin. N. Am. Equine Pract.* 6(1):1-30. <[http://dx.doi.org/10.1016/S0749-0739\(17\)30555-2](http://dx.doi.org/10.1016/S0749-0739(17)30555-2)> <PMid:2187565>
- Porto Alegre 2008. Institui, no município de Porto Alegre, o programa de redução gradativa do número de veículos de tração animal e de veículos de tração humana e dá outras providências. Lei Municipal nº 10.531, de 10 de setembro de 2008, Porto Alegre, RS.
- Price J., Catriona S., Welsh E.M. & Waran N.K. 2003. Preliminary evaluation of a behavior-based system for assessment of post-operative pain in horses following arthroscopic surgery. *Vet. Anaesth. Analg.* 30(3):124-137. <<http://dx.doi.org/10.1046/j.1467-2995.2003.00139.x>> <PMid:14498844>
- Pritchard J.C., Lindberg A.C., Main D.C. & Whay H.R. 2005. Assessment of the welfare of working horses, mules and donkeys, using health and behavior parameters. *Prev. Vet. Med.* 69(3/4):265-283.
- Proust S. 1991. Hitch for a Single-Shaft Horse-Drawn Vehicle. Publication number US5076041A of December 31, 1991, Patent Number 5,076,041, United States Patents. 7p.
- Rezende H.H.C. 2004. Impacto ambiental, perfil sócio-econômico e migração dos carroceiros em Belo Horizonte do setor formal para o informal no período de 1998 a 2003. Master's Thesis, Universidade Federal de Minas Gerais, Belo Horizonte. 61p.
- Rio de Janeiro 2016. Dispõe sobre a possibilidade de utilização de animais para fretamento de carroças e charretes no âmbito do estado do Rio de Janeiro e dá outras providências. Lei Estadual nº 7.194, de 07 de janeiro de 2016, Rio de Janeiro, RJ.
- Ross M. 2003. Lameness in horses: basic facts before starting, p.4. In: Ross M. & Dyson S. (Eds), *Diagnosis and Management of Lameness in the Horse*. W.B. Saunders, Philadelphia. <<http://dx.doi.org/10.1016/B978-0-7216-8342-3.50009-7>>
- Ross M.W. 2010. Lameness in horses: basic facts before starting, p.3-8. In: Ross M.W. & Dyson S.J. (Eds), *Diagnosis and Management of Lameness in the Horses*. 2nd ed. Elsevier Health Sciences, London.
- Souza M.F.A. 2006. Implicações para o bem estar de equinos usados para tração de veículos. *Revta Bras. Direito Anim.* 11:191-198.
- Stashak T.S. 2002. *Adams' Lameness in Horses*. 5th ed. Lippincott Williams and Wilkins, Baltimore. 1179p.
- Stashak T.S., Hill C., Klimesh R. & Ovnicke G. 2006. Cuidados com os cascos e colocação de ferraduras para equilíbrio e integridade, p.1015-1071. In: Stashak T.S. (Eds), *Claudicação em Equinos Segundo Adams*. 5ª ed. Roca, São Paulo.
- Thomassian A. 2005. *Enfermidades dos Cavalos*. 4ª ed. Varela, São Paulo, p.138-260.
- Veiga A.C.R. 2006. Estudo retrospectivo de casuística, abrangendo metodologia diagnóstica da osteoartrite em equinos. Master's Thesis, Universidade de São Paulo, São Paulo. 80p.
- Woodie J.B., Ruggles A.J. & Litsky A.S. 2000. *In vitro* biomechanical properties of 2 compression fixation methods for midbody proximal sesamoid bone fractures in horses. *Vet. Surg.* 29(4):358-363. <<http://dx.doi.org/10.1053/jvet.2000.5610>> <PMid:10917286>
- Yxklinten U. 1996. Evaluation of the sliding-phase between the hoof and ground for horses with rubbershoes (Öllöv original). Based on measurements by Drevemo S. & Johnston C. 1993, Swedish Agricultural University, Uppsala, Sweden.