

Morphometry of primary and secondary epidermal laminae in equine hoof¹

Luana S. Oliveira², André R.C. Barreto-Vianna², André S. Leonardo², Roberta F. Godoy² and Eduardo M.M. de Lima^{2*}

ABSTRACT.- Oliveira L.S., Barreto-Vianna A.R.C., Leonardo A.S., Godoy R.F. & Lima E.M.M. 2014. **Morphometry of primary and secondary epidermal laminae in equine hoof.** *Pesquisa Veterinária Brasileira* 34(1):79-82. Departamento de Anatomia Veterinária, Faculdade de Agronomia e Medicina Veterinária, Universidade de Brasília, ICC, Ala Sul, Campus Darcy Ribeiro, Cx. Postal 4508, Brasília, DF 70760-701, Brazil. E-mail: limaemm@unb.br

We studied the length of primary and secondary epidermal laminae of the toe and the lateral and medial quarters of horses, distributed into proximal, middle and distal thirds of the hooves. Eight limbs from adult crossbred horses, four females and four males, used to pull carts without pedal conditions. Fragments were taken from different regions of the hooves and subjected to conventional histological techniques. The samples were stained with hematoxylin-eosin and analyzed by light microscopy. The primary epidermal laminae were higher in the hooves of forelimbs compared to hindlimbs in the proximal and middle thirds and the regions of the medial quarter and toe. The secondary laminae were higher in forelimb of the middle third and medial quarter. Comparing the length of the epidermal laminae between hoof parts, it was seen that the primary laminae are lower in the proximal third and higher in the toe, while the secondary laminae are lower in the proximal third and medial quarter. The results suggested that the morphology of the laminae in the different regions of the hooves is influenced through the work performed by the animal, as well as through the different distribution of forces.

INDEX TERMS: Equine podiatry, hoof, length, morphophysiology, primary epidermal laminae, secondary epidermal laminae.

RESUMO.- [Morfometria das lâminas epidérmicas primárias e secundárias do casco de equinos.] Foi estudado o comprimento das lâminas epidérmicas primárias e secundárias da pinça e dos quartos lateral e medial, distribuídas nos terços proximal, médio e distal dos cascos de equinos. Utilizaram-se os membros de oito cavalos adultos utilizados para tração de carroças, que não apresentavam afecções podais, sendo quatro fêmeas e quatro machos, sem raça definida. Fragmentos foram retirados das diferentes regiões dos cascos e submetidos à técnica histológica convencional. As amostras foram coradas com H&E e analisadas em microscópio óptico. As lâminas epidérmicas primárias apresentaram-se maiores nos cascos dos membros torácicos em relação aos membros pélvicos nos terços proximal e médio

e nas regiões do quarto medial e na pinça. As lâminas secundárias foram maiores também no membro torácico no terço médio e no quarto medial. Comparando-se o comprimento das lâminas epidérmicas entre as regiões do casco, observou-se que as lâminas primárias são menores no terço proximal e maiores na pinça, enquanto as menores lâminas secundárias estão no terço proximal e no quarto medial. Os resultados sugerem que a morfologia das lâminas nas diversas regiões do casco sofre influência do trabalho realizado pelo animal, assim como, das diferentes distribuições de força existentes no mesmo.

TERMOS DE INDEXAÇÃO: Podologia equina, casco, comprimento, morfofisiologia, lâminas epidérmicas primárias, lâminas epidérmicas secundárias.

¹Received on February 21, 2013.

Accepted for publication on December 1, 2013.

²Departamento de Anatomia Veterinária, Faculdade de Agronomia e Medicina Veterinária, Universidade de Brasília, ICC Ala Sul, Campus Darcy Ribeiro, Cx. Postal 4508, Brasília, DF 70760-701, Brazil. *Corresponding author: limaemm@unb.br

INTRODUCTION

The equine hoof wall is formed by outer, middle and inner layers; the latter can also be called as laminar layer owing the presence of dermal and epidermal laminae, which protrude from the inner layer surface of the hoof wall parallel

to each other (Pollitt 2004). Primary epidermal laminae are larger and keratinized, and give rise to secondary epidermal laminae, which are smaller and non-keratinized (Pollitt 1992, Burg et al. 2007). These laminae interdigitate with dermal laminae, primary and secondary, and form the architecture of the laminar junction

The laminar junction has the attachment function between the distal phalanx and the hoof wall (Thomason et al. 2005). Thus the transfer of force between the ground and the bony skeleton occurs via hoof wall and laminar junction (Thomason et al. 2005). This laminar interface helps to reduce the stress and ensures a better distribution of the impact of the hoof on the ground (Pollitt 2004). The spaces between cell junctions in epidermal laminae allow the passage of nutrients, taking the role of capillaries in this avascular tissue (Pollitt 1992).

Primary epidermal laminae fill the entire inner surface of the hoof capsule, from the coronary band until the ground surface, along the circumference of the hoof (Lancaster et al. 2007). Each primary epidermal laminae gives rise to 20-200 secondary laminae (Pollitt 2004). Bidwell & Bowker (2006) consider that primary epidermal laminae in forelimbs are slightly more developed and longer than in hindlimbs.

There is evidence that the stress of laminar junction affects the modeling of primary epidermal laminae, determining a higher laminar density (Thomason et al., 2005). Changes in laminar morphology found in healthy horses cannot be considered normal or pathological, since it is not known whether these findings represent the normal range or manifestations of subclinical diseases (Lancaster et al. 2007). In trotter or English Thoroughbred horses (Thomason et al., 2008), is observed a primary epidermal laminae remodeling, induced by stress, but without a complete characterization of the relationship between stress or strain and remodeling process. Redden (2003) mentioned that the distortion of a component of the hoof capsule changes all other components and adjacent tissues. In this way, the large surface area of the connections between the dermal and epidermal laminae creates good mechanical strength, but at cellular level, these connections are quite fragile and susceptible to ischemia and enzymatic destruction (Redden 2003).

Given the above, it is necessary a better understanding of the morphophysiology of the laminar junction for developing methods for diagnosis and treatment of diseases (Lancaster et al. 2007), once equines are fairly dependent on an intact, functional and pain-free locomotor system (Pollitt 2004). Thus, with this motivation and seeking support to provide morphological and functional bases, this study aimed to depict morphometric aspects relative to primary and secondary epidermal laminae of equine hoof.

MATERIALS AND METHODS

We examined limbs of eight adult crossbred horses (four females and four males) used to pull carts, with 334kg average weight, and no locomotor disorders. Animals were collected in the Large Animal Veterinary Hospital of the University of Brasília after spontaneous death, and not related to the locomotor system. For each animal was used only one limb, forelimb or hindlimb, chosen at random. For collecting hooves, distal ends of the limbs

were disjointed at metatarsophalangeal and metacarpophalangeal joints to the fore- and hindlimbs, respectively. This study was approved by the Ethics Committee on Animal Use of the Biological Science Institute of the University of Brasília, under the protocol # 51203/2010.

Hooves which had hitherto been preserved by freezing, were thawed and sectioned with a band saw according to the protocol described by Pollitt (2006), being removed rectangular fragments of the hoof wall, with approximately 1cm³ each, containing the interface between dermal and epidermal laminae. Samples were removed from the toe of the hoof and from the lateral and medial quarters of each of them, according to Figure 1.

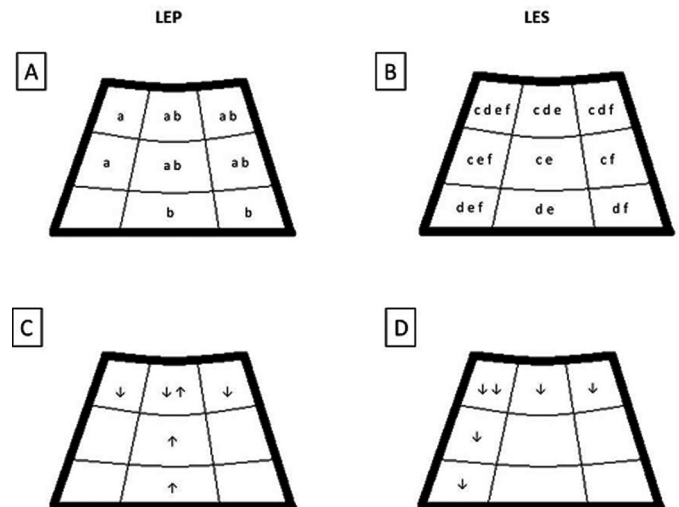


Fig.1. Diagram representative of equine hoof, dorsal view. Figures 3A and 3B represented, respectively, PEL and SEL. Similar letters indicate regions with statistical difference between fore- and hindlimbs. Figures 3C and 3D represent regions where PEL and SEL, respectively, presented longer (↑) or shorter (↓) length, considering both fore- and hindlimbs.

Fragments of laminar tissue were fixed in 10% formaldehyde aqueous solution. After fixation, the laminar interface was separated from the hoof wall and distal phalanx and subjected to conventional histological technique: dehydration with increasing concentrations of ethyl alcohol, being cleared in xylene, embed-

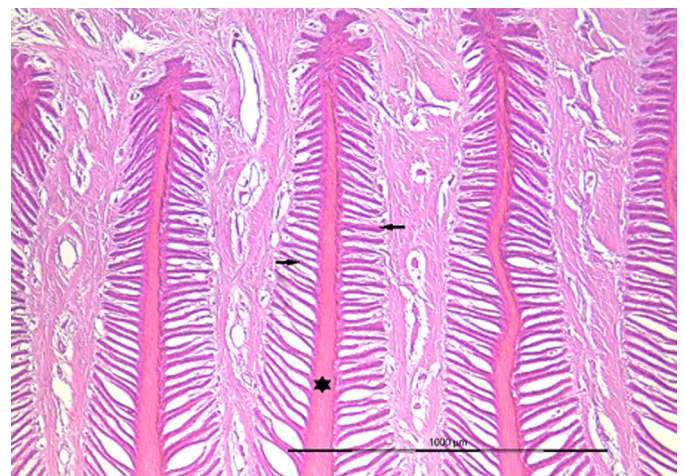


Fig.2. Laminar layer showing primary (asterisk) and secondary (arrow) epidermal laminae of the hoof of the left forelimb. HE, bar = 1000μm.

ded and impregnated in paraffin. Then blocks were sliced to a thickness of 4mm using a hand microtome (Leica RM 2125RT). To visualize and measure epidermal laminae, fragments were stained with hematoxylin-eosin (HE). Analysis of slides was performed under optical microscope (BX51 Olympus®). It was determined the length of primary and secondary epidermal laminae in several regions of fore- and hindlimbs, through a digital camera and image analysis software (ProgResCapturePro 2.5®) coupled to the microscope. The software allows measuring, in μm , histological structures analyzed, as represented in Figure 2.

Data were analyzed using the softwares Stat 3.5 and GraphPad Prism®5, subjected to Kolmogorov-Smirnov homoscedasticity test, checking the normality, and according to the respective characteristic of data, it was applied Student's t-test for parametric data or Mann-Whitney test for non-parametric data, comparing the two regions between fore- and hindlimbs. An analysis of variance (ANOVA) was employed, followed by the Tukey's test, when compared the three regions of the same limb. In statistical analyses, we considered $p \leq 0.05$ as significantly different.

RESULTS AND DISCUSSION

Histological slides of samples used in this study were processed and images of primary and secondary epidermal laminae have become feasible for measuring lengths (Fig.2).

The mean and standard error of length of primary epidermal laminae (PEL) considering all samples of fore- and hindlimbs was $2596 \pm 34.11 \mu\text{m}$, and the length of secondary epidermal laminae (SEL) was $151.5 \pm 1.694 \mu\text{m}$. These values are in line with the study of Sampaio (2007) who reported corresponding values for the control group of the respective experiment. Primary epidermal laminae presented statistical difference relative to proximal and middle thirds and between medial quarters and the toe of the hoof, considering that these laminae were larger for the forelimb than in hindlimb (Fig.3A and 3B).

Secondary epidermal laminae showed statistical difference in the proximal third and in the medial quarter, relative

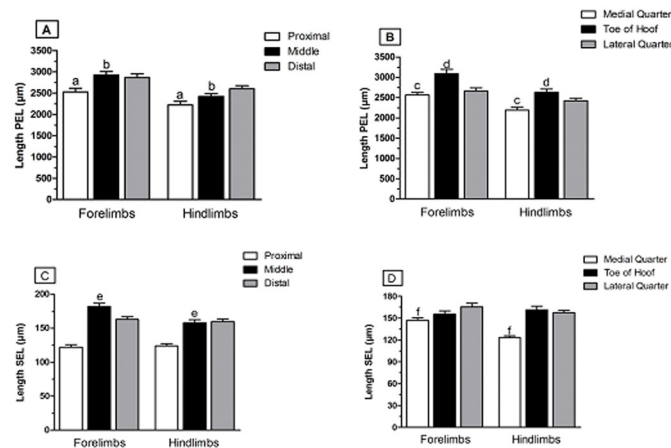


Fig.3. Mean and standard error of lengths of PEL and SEL in fore- and hindlimbs. Columns with similar letters indicate regions with statistical difference between hooves of fore- and hindlimbs. (A) Length of PEL in proximal, middle, and distal thirds of the hoof. (B) Length of PEL in the toe of the hoof and in lateral and medial quarters. (C) Length of SEL in proximal, middle, and distal thirds of the hoof. (D) Length of SEL in the toe of the hoof and in lateral and medial quarters.

ve to other regions (Fig.3C and 3D). Likewise PEL, SEL were also larger in forelimb than in hindlimb (Fig.3A-D).

Among the measurements for primary epidermal laminae for fore- and hindlimbs, it was evidenced that the toe of the hoof presented longer PEL in relation to lateral and medial quarters, and the proximal third presented the shortest PEL in relation to other thirds (Fig.4A and 4B). In the same way, a difference was found between thirds and quarters in relation to the length of secondary epidermal laminae, so that the proximal third and the medial quarter were the smallest SEL (Fig.4C and 4D).

In the present study, primary epidermal laminae were on average 14.8% longer in the forelimb, as also observed by

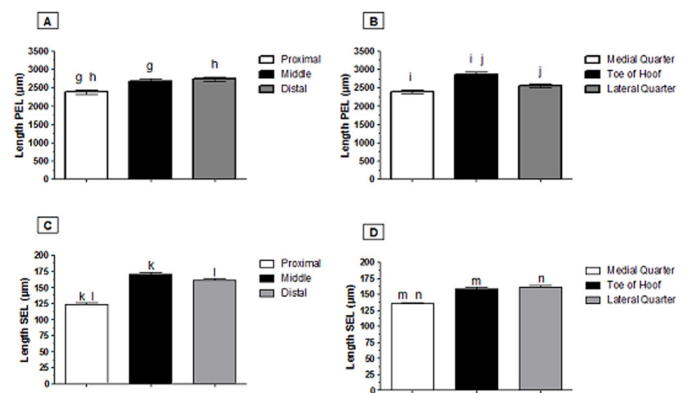


Fig.4. Mean and standard error of lengths of PEL and SEL in different regions of the hoof. Columns with similar letters indicate regions with statistical difference. (A) Length of PEL in proximal, middle, and distal thirds of the hoof. (B) Length of PEL in the toe of the hoof and in lateral and medial quarters. (C) Length of SEL in proximal, middle, and distal thirds of the hoof. (D) Length of SEL in the toe of the hoof and in lateral and medial quarters.

Sampaio (2007), where this value was 16.5% and associated to the higher load weight to which forelimbs are subjected to. Similarly, the length of SEL was longer in forelimbs. These results are comparable to those registered by Bidwell & Bowker (2006). Since that increases of bifurcation and of length of primary and secondary epidermal laminae contribute with variations in laminar joint, it is possible to support the idea that the normal laminar apparatus is able to respond to mechanical load (Sarratt & Hood, 2005).

Thomason et al. (2008) have associated changes in the hoof capsule with changes in the laminar joint, suggesting a remodeling of primary epidermal laminae induced by stress. Thus, the change of one of the components of the hoof capsule alters adjacent structures, once the hoof acts as an integrated unit (Redden 2003). This information agrees with observations of Sampaio (2007) who mentioned that the length of primary epidermal laminae had been related to the load weight borne by the hoof.

Otherwise, problems such as unevenness of the heel or elongation of the toe of the hoof, for example, would lead to an uneven distribution of the animal weight on the hoof during the impact with the surface (Melo et al. 2006). In addition to possibly influence the length of primary and secondary epidermal laminae in different regions of the hoof, it is known

that asymmetries in weight distribution on the hoof can cause rotation and sliding of distal phalanges (Denoix 1999).

Given these considerations regarding unbalance forces acting on the hoof, metric data found herein are in accordance with the expected, once animals employed were collected at random and none had been subjected to corrective hoof trimming, explaining the fact that both PEL and SEL of the proximal third were shorter in relation to other thirds, and PEL of the toe of the hoof were larger, and SEL of the medial quarter were shorter. Both primary and secondary epidermal laminae presented shorter length in the proximal region of the hoof (Fig.4A and 4C), probably because laminae are formed from the coronary band and continuously increase the hoof wall (Pollitt 2004).

CONCLUSION

Metric data found in this study represent an initial proposal that suggests an understanding of the architecture of equine hoof and allow the establishment of parameters that can be used as an aid in the diagnosis and prognosis of diseases that affect this structure.

REFERENCES

- Bidwell L.A. & Bowker R.M. 2006. Evaluation of Changes in Architecture of the Stratum Internum of the Hoof Wall from Fetal, Newborn, and Yearling Horses. *Am. J. Vet. Res.* 67:1947-1955.
- Burg E., Diepenbroek C., Hoorneman N. & Lichtenberg E. 2007. Explorative Study of the Natural Balance Method of Hoof Care in Horses. Wageningen University and Research Center, Wageningen.
- Lancaster L.S., Bowker R.M. & Mauer W.A. 2007. Density and Morphologic Features of Primary Epidermal Laminae in the Feet of Three-Year-Old Racing Quarter Horses. *Am. J. Vet. Res.* 68(1):11-19.
- Melo U.P., Ferreira C., Santiago R.M.F.W., Palhares M.S. & Maranhão R.P.A. 2006. Equilíbrio do casco equino. *Ciênc. Anim. Bras.* 7(4):389-398.
- Pollitt C.C. 1992. Clinical anatomy and physiology of the normal equine foot. *Equine Vet. Educ.* 4(5):219-224.
- Pollitt C.C. 1996. Basement membrane pathology: a feature of acute equine laminitis. *Equine Vet. J.* 28(1):38-46.
- Pollitt C.C. 2004. Anatomy and Physiology of the Inner Hoof Wall. *Equine Vet. J.* 3(1):3-21.
- Redden R.F. 2003. Hoof capsule distortion: understanding the mechanisms as a basis for rational management. *Vet. Clin. North Am., Equine Pract.* 19(2):443-462.
- Sampaio R.C.L. 2007. Laminite experimental: aspectos morfológicos, morfométricos e ultra-estruturais das lâminas dérmicas e epidérmicas do casco de eqüinos tratados com a trinitroglicerina. Universidade Estadual Paulista Julio de Mesquita Filho, Jaboticabal, SP.
- Thomason J.J., Faramarzi B., Reville A. & Sears W. 2008. quantitative morphology of the equine laminar junction in relation to capsule shape in the forehoof of Standardbreds and Thoroughbreds. *Equine Vet. J.* 40(5):473-480.
- Thomason J.J., McClinchey H.L., Faramarzi B. & Jofriet J.C. 2005. Mechanical behavior and quantitative morphology of the equine laminar junction. *Anat. Rec. A, Discov. Mol. Cell Evol. Biol.* 283(2):366-379.